




## Research Article

## Apparent Diffusion Coefficient in the Diagnosis and Follow-up of Multiple Sclerosis: Role of Magnetic Resonance Imaging

Zainab Omer Ahmed<sup>1</sup>, Haitham Khudair Dema<sup>2</sup>, Oday Talal Yehia<sup>3</sup>, Khalida Ibrahim Noel<sup>4\*</sup> 

<sup>1</sup>Department of Radiology, Medical Research Hospital, Mosul Health Directorate, Mosul, Iraq; <sup>2</sup>Department of General Surgery, Mosul General Hospital, Mosul Health Directorate, Mosul, Iraq; <sup>3</sup>Department of Radiology, Al-Jumhuri Hospital, Mosul Health Directorate, Mosul, Iraq; <sup>4</sup>Department of Human Anatomy, College of Medicine, Mustansiriyah University, Baghdad, Iraq

Received: 1 July 2024; Revised: 11 August 2024; Accepted: 14 August 2024

## Abstract

**Background:** Chronic Multiple Sclerosis (MS) modifies the apparent diffusion coefficient (ADC) value due to severe pathological changes. After trauma, it is the second most common cause of brain injury in healthy young adults. MRI is considered the initial imaging modality for MS diagnosis and follow-up. **Objective:** To assess the significance of the ADC in the diagnosis and follow-up of MS plaques across various disease subtypes. **Methods:** Forty MS patients were included in a case-control study at Ibn-Sina Teaching Hospital, Mosul Province, between June 1, 2022 and February 28, 2023. The patients had diffusion-weighted and traditional MR imaging with ADC measurement in plaques, and the normal white matter value of controls was compared to the patients' results. **Results:** The ADC values were higher in cases that were acute or secondary-progressive than in relapsing-remitting cases or normal white matter. In both types of newly generated plaques, there was an initial non-significant increase in ADC values compared to existing plaques. Overall, the ADC sensitivity, specificity, and accuracy in diagnosing MS were 85.7%, 95.2%, and 90.5% in acute cases, and 85.7%, 83.3%, and 84.6% in chronic cases, respectively, with no significant difference between active and inactive lesions. **Conclusions:** The apparent diffusion coefficient value can be included in the imaging protocol for the diagnosis and follow-up of various subtypes of MS.

**Keywords:** Apparent diffusion coefficient (ADC), Brain MRI, Multiple sclerosis.

معامل الانتشار الظاهر في تشخيص ومتابعة التصلب المتعدد: دور التصوير بالرنين المغناطيسي

الخلاصة

**الخلفية:** يغير التصلب المتعدد (MS) المزمّن قيمة معامل الانتشار الظاهر (ADC) بسبب التغيرات المرضية الشديدة. بعد الصدمة، هو السبب الثاني الأكثر شيوعاً لإصابة الدماغ لدى الشباب الأصحاء. يعتبر التصوير بالرنين المغناطيسي طريقة الفحص الأولية لتشخيص مرض التصلب العصبي المتعدد ومتابعته. **الهدف:** تقييم أهمية ADC في تشخيص ومتابعة لويحات مرض التصلب العصبي المتعدد عبر أنواع فرعية مختلفة من المرض. **الطريقة:** تم تضمين أربعين مريضاً بالتصلب المتعدد في دراسة الحالات والشواهد في مستشفى ابن سينا التعليمي بمحافظة الموصل بين 1 يونيو 2022 و 28 فبراير 2023. كان لدى المرضى تصوير بالرنين المغناطيسي مرجح الانتشار وتقليدي مع قياس ADC في اللويحات، وتمت مقارنة قيمة المادة البيضاء الطبيعية للضوابط بنتائج المرضى. **النتائج:** كانت قيم ADC أعلى في الحالات الحادة أو الثانوية التقدمية مقارنة بحالات الانتكاس أو المادة البيضاء العادية. في كلا النوعين من اللويحات التي تكونت حديثاً، كانت هناك زيادة أولية غير كبيرة في قيم ADC مقارنة باللويحات الموجودة. بشكل عام، كانت حساسية ADC ونوعيتها ودقتها في تشخيص مرض التصلب العصبي المتعدد 85.7% و 95.2% و 90.5% في الحالات الحادة و 85.7% و 83.3% و 84.6% في الحالات المزمنة على التوالي، مع عدم وجود فرق كبير بين الأوقات النشطة وغير النشطة. **الاستنتاجات:** يمكن تضمين قيمة معامل الانتشار الظاهري في بروتوكول التصوير لتشخيص ومتابعة الأنواع الفرعية المختلفة من مرض التصلب العصبي المتعدد.

\* **Corresponding author:** Khalida I. Noel, Department of Human Anatomy, College of Medicine, Mustansiriyah University, Baghdad, Iraq; Email: [dr.khalidanoel@uomustansiriyah.edu.iq](mailto:dr.khalidanoel@uomustansiriyah.edu.iq)

**Article citation:** Ahmed ZO, Dema HK, Yehia OT, Noel KI. Apparent Diffusion Coefficient in the Diagnosis and follow-up of Multiple Sclerosis: Role of Magnetic Resonance Imaging. *Al-Rafidain J Med Sci.* 2024;7(1):133-138. doi: <https://doi.org/10.54133/ajms.v7i1.1114>

© 2024 The Author(s). Published by Al-Rafidain University College. This is an open access journal issued under the CC BY-NC-SA 4.0 license (<https://creativecommons.org/licenses/by-nc-sa/4.0/>).



## INTRODUCTION

Multiple sclerosis is a condition characterized by persistent demyelination of the central nervous system (CNS), with inflammation and demyelination acting as clinical markers. Axon and gliosis loss primarily affects

the periventricular region of the brain stem, optic nerves, spinal cord, and white matter, but it also affects gray matter [1]. It is thought to be the second most prevalent brain injury after trauma. Therefore, MS affects distinct brain regions both spatially and temporally, spreading

over time. Plaque is one of these diseases' features. MRI is regarded as the best imaging modality for both diagnosis and follow-up [2]. Diffusional MRI sequences are utilized to look beneath tissue that has microstructural abnormalities and alterations that are not visible or picked up by traditional MRI sequences. Diffusion depends on the water particles that are present in the tissue, which move equally in all directions in an isotropic manner. However, the influence of this disease is reduced on the tissues, and to a lesser extent, even on the gray matter [3]. Because of this, these limitations on traditional research can be ignored when using quantitative images to show markers for apparent diffusion coefficients that are better at finding pathological abnormalities [4]. Because of demyelination and extracellular vasogenic edema, ADC identified lesions with acute onsets as having greater ADC values than chronic lesions [5]. Because the plaque's location varies and changes over time, the clinical presentation is highly variable during the acute stage of the disease [6]. While the primary cause of MS development is unknown, acquired and genetic factors play a role. Case groups and geographical spread have shown that the infectious agents (like EBV) or at least the catalyst are no longer thought to be the cause. As a result, no clear mediator has been found yet [7]. Additionally, some writers suggested that "chronic cerebrospinal venous insufficiency" may be the cause of or a worsening of MS; however, further testing has not supported this theory [8]. People with MS don't lose many oligodendrocytes or axons in the early stages because their immune systems aren't attacking their specific myelination modules [9]. But as the disease gets worse, axon damage leads to oligodendrocyte loss [10]. Demyelination occurs in specific foci in the perivenular area, called "plaques." These foci vary in size from a few millimeters to a few centimeters. MRI has transformed MS patient monitoring and diagnosis [11]. MRI not only confirms results, but follow-up pictures also reveal changes in the disease's course and guide treatment [12]. The 2018 Revised Guidelines of the Consortium of MS Centers MRI Protocol for the Diagnosis and Follow-up of Plaques in MS included a list of the following sequences, which are among the numerous contributing sequences in the imaging protocol [13]: 1) FLAIR in both the axial and sagittal directions; 2) T1 gradient echo prepared for 3D inversion recovery; 3) Axial T2 image, two- or three-dimensional; and 4) Axial DWI view. The clinical, radiographic, and laboratory criteria used in the diagnosis of multiple sclerosis are known as the McDonald diagnostic criteria. Numerous revisions have occurred since their introduction in 2001, with the most recent one taking place in 2017 [13]. The aim of this research is to establish the role of ADC value in the analysis and prognosis of MS patients in various clinical types of disease.

## **METHODS**

### ***Study settings and design***

A prospective case control study was carried out from June 1, 2022, to February 28, 2023, at the Ibn Sina Teaching Hospital in the Mosul area of Iraq. Twenty individuals in excellent health served as the control group. The study included a total of 40 MS patients (25 females and 15 males) with various clinical subtypes.

### ***Data collection***

The non-probability convenience sampling approach is used to gather the sample. The information was gathered by history, clinical presentation, and type of MS. Every patient underwent examination using diffusion-weighted and conventional MR imaging, and those with acute MS underwent a follow-up MRI six months following the initial study to reevaluate their lesions.

### ***Inclusion criteria***

The study included MS patients who were either outpatients or referred for a brain MRI by the neurology department. The McDonald diagnostic criteria were used to diagnose these patients.

### ***Exclusion criteria***

Presence of contraindications to the MRI examination (pacemaker, vascular clips, pregnancy). Patients suffering from ischemic or inflammatory brain diseases, among other intracranial pathologies.

### ***Ethical consideration***

The Arab Council of Health Specialization granted ethical approval after all participants gave their informed consent and were informed of the study's purpose.

### ***Technique of examination***

Every MRI study was conducted with a 1.5 Tesla Philips MR scanner. Every patient was instructed to discard any items made of metal or gold. The length of the examination, the position, and the need to maintain stillness and calm breathing were explained to the patients. The patient was placed in a supine position and an ordinary head coil was used to do the MRI study. In this study, we recorded the axial proton density (PD), the T2-weighted turbo spin-echo sequence, and the axial T1-weighted spin-echo sequence before and after GBCAs were injected at a dose of 0.1 mmol/kg of body weight. The number and location of Gd+ lesions on the first MRI scan (periventricular, subcortical, juxtacortical, brainstem, and cerebellum) were calculated. Normal white matter (NWM) was examined in the control group and normal-appearing white matter (NAWM) in the MS group for the ADC value. Two radiology specialists evaluated each MRI of the brain centrally. All cases were investigated according to the following procedures:

Sagittal T1 W1 as a localizer: (TE = 0–12 m/sec, TR = 400–600 m/sec)

Axial T1-weighted images: (TE = 1 0–12 m/sec, where 400–600 m/sec is TR)

The images are axial and coronal fast spin-echo T2-weighted, with a TE of 70–90 m/sec and a TR of 2800–3500 m/sec.

Multiplanar (axial, sagittal and coronal) FLAIR (fluid-attenuated inversion-recovery) sequences: TR = 9000/9400 m/sec. TE is equal to 119/150 meters per second. The TI ranges from 2470 to 2800 m/sec. FOV is equal to 24–18 cm in axial pictures and 30–22 cm in coronal images. The matrix has dimensions of (phase x frequency) 192 x 160, with a slice thickness of 5 mm at intervals of 1 mm. (Throughout every sequence).

### MR imaging using diffusion weighted techniques

The DWI was performed using a multi-section single-shot spin echo EPI sequence with (TR/TE/NEX: 4200/140 ms/I) and a B value (diffusion sensitivity) of 0 and 1000 s/mm<sup>2</sup>. Diffusion gradients were applied in three orthogonal directions (X, Y, and Z). Five-millimeter slices with a one-millimeter gap between them were utilized. The field of view (FOV) was set to 240mm, the matrix size was set to 128\*256, and the acquisition time was completed in 80 seconds. The ADC sequence's maps were generated automatically by computer software and displayed in the sequence. In MS patients, ADC measurements were taken in both normal white matter and demyelination plaques. After that, the ADC values' means were calculated and expressed. The ADC values were measured in the normal white matter of the twenty healthy controls.

### Statistical analysis

The Microsoft Excel 2013 version was used to save data and analyze it. Measures of central tendency and dispersion for continuous variables were used in the descriptive analysis process. Frequency and percent were used to characterize the category variables. Sensitivity, specificity, and accuracy of the test were computed, and  $p < 0.001$  was considered for statistical significance.

## RESULTS

The study included forty MS patients, ages ranging from 20 to 45 years, with a mean of 32.5 years. Of the sample, 25 were female and 15 were male. Twenty normal, healthy individuals (12 females and 8 males) make up the control group. Patients were primarily categorized into two groups using ADC value measurements according to the duration and clinical course: Group B comprised 29 patients with chronic MS cases, further subdivided into two subgroups: 18 individuals with relapsing remitting cases (B1) and 11 patients with progressive disease (B2; Table 1). For acute cases, the ADC value on the first scan was higher than for controls, where the white matter looked normal (mean  $1.12 \pm 0.1 \times$

$10^{-3} \text{ mm}^2/\text{sec}$  for acute cases, mean  $0.30 \pm 0.02 \times 10^{-3} \text{ mm}^2/\text{sec}$  for controls).

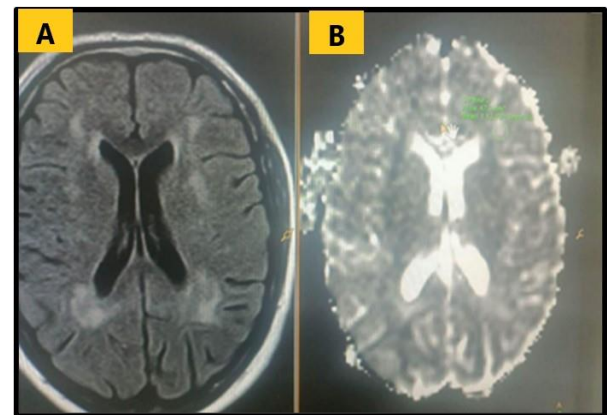
**Table 1:** Types of multiple sclerosis according to the clinical course

Types of MS	n(%)
(A) Acute cases	11(27.5)
(B) Chronic cases	29(72.5)
B1. Relapsing Remitting cases	18(62)
B2. Progressive cases	11(38)
Total	40(100)

Eleven patients who were exhibiting a clinically aggressive course underwent a follow-up MRI scan; the scan was postponed for the next six months. Eight out of eleven cases had a decreased ADC value from the first scan; these cases were clinically diagnosed as having a relapsing remitting course (mean  $1.01 \pm 0.12 \times 10^{-3} \text{ mm}^2/\text{sec}$ ). The remaining three cases showed a persistently elevated ADC value ( $1.35 \pm 0.3 \times 10^{-3} \text{ mm}^2/\text{sec}$ ); these patients had a progressive pattern of the disease (Table 2) (Figure 1).

**Table 2:** The ADC value of the MS cases in follow up expressed in acute cases

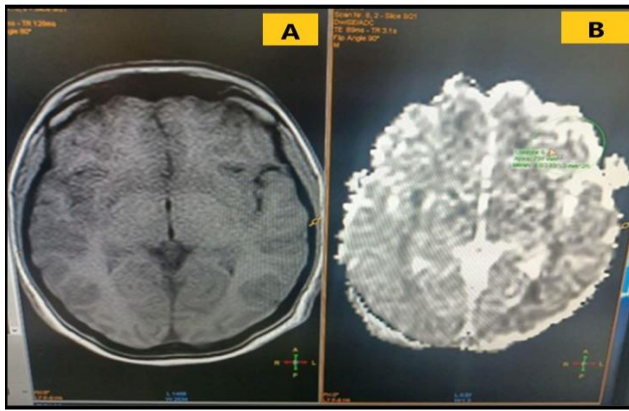
ADC value	No(%)
Total acute cases	11(100)
1.12 progressive cases	3(27.27)
<1.12 Relapsing Rem	8(72.72)



**Figure 1:** Brain MRI of 32-years-old male patient diagnosed as having an acute MS of relapsing remitting course. The patient had a history of one-week duration sudden onset of right upper limb weakness. (A) Axial FLAIR sequence shows multiple high signal intensities plaques in the periventricular white matter. (B) ADC sequence in which ADC value of the abnormal high signal lesion was  $1.12 \times 10^{-3} \text{ mm}^2/\text{sec}$ .

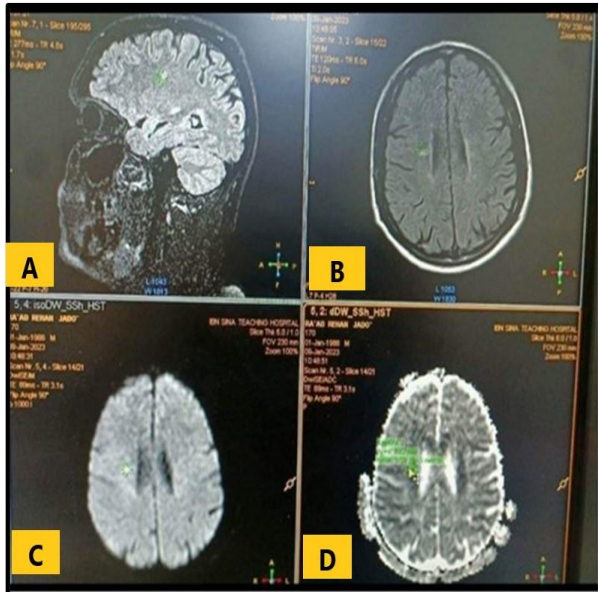
Regarding the chronic cases of multiple sclerosis (MS), which comprise 29 patients, the mean ADC value was  $1.03 \pm 0.11 \times 10^{-3} \text{ mm}^2/\text{sec}$  on the 1<sup>st</sup> MRI scan for the relapsing-remitting patients (B1= 18 patients). After six months of medical treatment, they underwent another scan, and this time, the ADC value was measured. The mean ADC value was  $0.31 \pm 0.05 \times 10^{-3} \text{ mm}^2/\text{sec}$ , which is a statistically significant reduction from the initial scan. Additionally, there was a noticeable clinical improvement in the patients' symptoms, indicating a favorable response to treatment (Figure 2).





**Figure 2:** Brain MRI scan of a 37-years old female who is a known case of chronic MS on medical treatment, of relapsing remitting type, presented with right sided upper limb weakness, (A & B) Axial T1 W1 and ADC sequences show few high signal plaques in the left frontal lobe. In the ADC map: the plaques are of high Signal intensity as well with ADC value of  $1.03 \times 10^{-3} \text{mm}^2/\text{sec}$ .

In patients with chronic progressive disease (B2 = 11 patients), the mean ADC value on the first scan was found to be  $1.59 \pm 0.10 \times 10^{-3} \text{mm}^2/\text{sec}$ . This relatively high value was shown to be persistent when compared to the follow-up value that measured  $1.33 \pm 0.05 \times 10^{-3} \text{mm}^2/\text{sec}$  6 months later. However, the patient's medical records indicated a lack of improvement or even decline in clinical courses (Figure 3).



**Figure 3:** Brain MRI of 39 years old male patient who is on treatment for having chronic MS of progressive pattern, his presentation was left upper limb weakness. (A) Sagittal T2WI (B) axial FLAIR display periventricular hyperintense lesions (C) Axial DW and (D) ADC restricted diffusion. The ADC value right periventricular lesion was elevated ( $1.59 \pm 0.10 \times 10^{-3} \text{mm}^2/\text{sec}$ ).

For the newly developed plaques: The follow-up scans of all the studied patients revealed that all newly developed plaques had a relatively high ADC value compared to NAWM. However, there were no statistically significant differences between the various clinical types and subtypes. The mean ADC value for new plaques in acute

cases was  $1.4 \pm 0.07 \times 10^{-3} \text{mm}^2/\text{sec}$ . In relapsing remitting (RR) cases, the mean ADC value for new plaques was  $1.5 \pm 0.09 \times 10^{-3} \text{mm}^2/\text{sec}$ . The mean ADC value for new in primary progressive (PP) cases was  $1.52 \pm 0.1 \times 10^{-3} \text{mm}^2/\text{sec}$ . Furthermore, Table 3 reveals that the mean ADC value of newly diagnosed plaques is higher than that of old plaques and NAWM. The results demonstrate the validity of using the ADC value to diagnose multiple sclerosis (MS) by measuring sensitivity, specificity, and accuracy.

**Table 3:** Distribution of mean ADC values (mm<sup>2</sup>/sec) of newly developed plaques according to the MS clinical types and subtypes

Variable	Acute (n=2)	Relapsing (n=4)	Progressive (n=4)	p-value
Mean±SD	1.4±0.07	1.5±0.09	1.52±0.10	0.72
Range	1.32-1.45	1.41-1.62	1.44-1.70	

For acute cases, the values are 85.7% (sensitivity), 95.2% (specificity), and 90.5% (accuracy); for chronic cases, the values are 85.7 (sensitivity), 83.3 (specificity), and 84.6 (accuracy); the difference between acute and chronic cases is statistically significant (Table 4).

**Table 4:** Validity of the ADC value in the MS diagnosis

MS Type	Sensitivity	Specificity	Accuracy	p-value
Acute	85.7	95.5	90.5	0.001
Chronic	85.7	83.3	84.6	0.001

Lesions that showed restricted diffusion and incomplete ring enhancement in contrast studies were considered active lesions for patients with active lesions, while other lesions were considered inactive. The mean ADC values of these lesions were shown to be  $1.59 \pm 0.04 \times 10^{-3} \text{mm}^2/\text{sec}$ ; this value looks higher in comparison with that of inactive lesions (the mean ADC value was  $1.31 \pm 0.06 \times 10^{-3} \text{mm}^2/\text{sec}$ ), and no statistically significant differences were recorded between these two types of lesions ( $p > 0.05$ ) (Table 5).

**Table 5:** ADC values in active and non-active lesions

Variable	Active lesion	Inactive lesion	p-value
ADC mm <sup>2</sup> /sec	$1.37 \pm 0.04 \times 10^{-3}$	$1.31 \pm 0.06 \times 10^{-3}$	>0.05

## DISCUSSION

DWI is acknowledged as a unique MR contrast sequence that enables the measurement of water molecules' diffusional motion [14]. Several diseases alter the characteristics of water diffusion, thereby impacting molecular movement in living tissue. With DW-MRI, these changes may be measured in vivo. While DW-MRI has been historically used to assess cerebral ischemia, its application to demyelinating brain illnesses is growing, with a particular focus on determining the extent and severity of MS pathology [15]. Compared to the ADC value of NWM in the control group, ADC values in the plaques were found to be substantially higher in cases with acute MS, with a mean duration of clinical symptoms of 12 days ( $p < 0.001$ ). The ADC values of acute MS plaques and the

NAWM differed statistically according to the study of Hartung *et al.* [13]. In the present investigation, the average ADC value for acute plaques was higher than the control case NWM value, and the mean ADC value for acute plaques was higher than that reported in NAWM. Additionally, these outcomes agreed with the findings published by Filippi *et al.* [16]. The mean ADC value in patients classified as chronic was  $0.88 \pm 0.06 \times 10^{-3} \text{ mm}^2/\text{sec}$  in their NAWM and  $1.03 \pm 0.1 \times 10^{-3} \text{ mm}^2/\text{sec}$  in the plaques of clinically confirmed relapsing remitting individuals. The average ADC value, on the other hand, was  $1.59 \pm 0.1 \times 10^{-3} \text{ mm}^2/\text{sec}$  in the plaques of the chronic progressive cases and  $0.88 \pm 0.08 \times 10^{-3} \text{ mm}^2/\text{sec}$  in their NAWM, compared to  $0.30 \pm 0.02 \times 10^{-3} \text{ mm}^2/\text{sec}$  in the control participants NWM. A study by Almolla *et al.* [17] looked at MS patients with lesions and found that the ADC values of chronic lesions were statistically higher than those of normal healthy white matter (NHWM) and non-atherosclerotic white matter (NAWM). Their findings were similar to ours. We found that among patients with chronic MS, progressive cases had plaque values of ADC that were substantially higher than those of relapsing-remitting cases ( $p < 0.001$ ). The findings show that when distinguishing between acute and normal cases, matching sensitivity, specificity, and accuracy of 85.7%, 95.2%, and 90.5% were attained [18,19]. The findings of Ragheb *et al.*, who showed 93.7% sensitivity, 94.3% specificity, and 85% accuracy, are consistent with our results [20]. In agreement with Castriota *et al.* [18], the results for relapsing and progressive cases were 85.7%, 83.3%, and 84.6%, respectively, in addition to Ragheb *et al.* [20], who found that the sensitivity, specificity, and accuracy for chronic cases were 89.3%, 85%, and 84.6%, respectively. As per Davoudi *et al.* [21], our study revealed that the assessed ADC value in MS lesions could be employed for both MS diagnosis and monitoring the progress. The mean ADC value was  $1.59 \times 10^{-3} \text{ mm}^2/\text{sec}$  for active lesions and  $1.31 \times 10^{-3} \text{ mm}^2/\text{sec}$  for inactive lesions, and a statistically significant difference was not seen. When patients with and without active lesions were compared, the ADC values for active and inactive lesions were statistically insignificant ( $p > 0.050$ ). Terzi *et al.* [22] discovered comparable findings and stated that whereas active lesions had higher ADC values than NAWM, the ADC levels of chronic and active lesions did not differ significantly. Furthermore, the current study agrees with that reported by Unal *et al.* [23], which revealed that there was no statistically significant ADC difference between active and chronic lesions and that both groups had statistically significantly higher ADC values than NAWM and NHWM.

## Conclusion

Quantifying the ADC value in MS lesions can aid in differentiating between the various subtypes of the disease.

## Recommendations

Improving the diagnosis of multiple sclerosis (MS) can be achieved by identifying the clinical subtype of the illness and evaluating the response to treatment using imaging procedures. This includes assessing DWI (diffusion-weighted imaging) and ADC (apparent diffusion coefficient) values during the initial scan and follow-up.

## Conflict of interests

No conflict of interests was declared by the authors.

## Funding source

The authors did not receive any source of fund.

## Data sharing statement

Supplementary data can be shared with the corresponding author upon reasonable request.

## REFERENCES

1. Confavreux C, Vukusic S, Moreau T, Adeleine P. Relapses and progression of disability in multiple sclerosis. *N Engl J Med.* 2000;343(20):1430-1438. doi: 10.1056/NEJM200011163432001.
2. Sarbu N, Shih RY, Jones RV, Horkayne-Szakaly I, Oleaga L, Smirniotopoulos JG. White matter diseases with radiologic-pathologic correlation. *Radiographics.* 2016;36(5):1426-1447. doi: 10.1148/rg.2016160031.
3. Okuda DT, Mowry EM, Beheshtian A, Waubant E, Baranzini SE, Goodin DS, et al. Incidental MRI anomalies suggestive of multiple sclerosis: the radiologically isolated syndrome. *Neurology.* 2009;72(9):800-805. doi: 10.1212/01.wnl.0000335764.14513.1a.
4. Garaci FG, Marziali S, Meschini A, Fornari M, Rossi S, Melis M, et al. Brain hemodynamic changes associated with chronic cerebrospinal venous insufficiency are not specific to multiple sclerosis and do not increase its severity. *Radiology.* 2012;265(1):233-239. doi: 10.1148/radiol.12112245.
5. Bakshi R, Minagar A, Jaisani Z, Wolinsky JS. Imaging of multiple sclerosis: role in neurotherapeutics. *NeuroRx.* 2005;2(2):277-303. doi: 10.1602/neurorx.2.2.277.
6. Mohammed F, Ismail M. Validity of apparent diffusion coefficient value in diagnosis and follow up of multiple sclerosis patients in different clinical subtypes. *Egypt J Radiol Nuclear Med.* 2018;49(4):1103-1109. doi: 10.1016/j.ejrm.2018.07.006.
7. McNamara C, Sugrue G, Murray B, MacMahon PJ. Current and emerging therapies in multiple sclerosis: Implications for the radiologist, Part 1-Mechanisms, efficacy, and safety. *Am J Neuroradiol.* 2017;38(9):1664-1671. doi: 10.3174/ajnr.A5147.
8. Daoud AG, Waheed HJ, Abdala ME. The Impact of Vitamin D on The Development of Multiple Sclerosis (Review article). *Al Mustansiriyah J Pharm Sci.* 2022;21(3):7-15. doi: 10.32947/ajps.v21i3.792.
9. Salih KM, Abdullah AH, Sheaaheed NM. Assessment of some platelet activating markers and secretory status with clinical manifestations in multiple sclerosis Iraqi patients. *Al-Mustansiriyah J Sci.* 2022;33(3):12-19. doi:10.23851/mjs.v33i3.1130.
10. Zabirowa AK, Bakulin IS, Poydasheva AG, Zakharova MN, Suponeva NA. Cognitive impairment and its treatment in patients with multiple sclerosis. *Almanac Clin Med.* 2023;51(2):110-125. doi: 10.18786/2072-0505-2023-51-009.
11. Chang CA, Chong AL, Chandra RV, Butler E, Rajendran D, Chuah K, et al. Detection of multiple sclerosis lesions in the cervical cord: which of the MAGNIMS 'mandatory' non-gadolinium enhanced sagittal sequences is optimal at 3T? *Neuroradiol J.* 2021;34(6):600-606. doi: 10.1177/19714009211017787.

12. Thompson AJ, Banwell BL, Barkhof F, Carroll WM, Coetzee T, Comi G, et al. Diagnosis of multiple sclerosis: 2017 revisions of the McDonald criteria. *Lancet Neurol.* 2018;17(2):162-173. doi: 10.1016/S1474-4422(17)30470-2.
13. Hartung HP, Graf J, Aktas O, Mares J, Barnett MH. Diagnosis of multiple sclerosis: revisions of the McDonald criteria 2017 - continuity and change. *Curr Opin Neurol.* 2019;32(3):327-337. doi: 10.1097/WCO.0000000000000699.
14. Fahad QA, Hadi AS, Obaid SF. A comparison of sagittal sections of short T1inversion recovery and T2 weighted fast spin echo magnetic resonance sequences for detection of multiple sclerosis spinal cord lesions. *Al-Kindy Coll Med J.* 2016;12(2):60-63.
15. Filippi M, Inglese M. Overview of diffusion-weighted magnetic resonance studies in multiple sclerosis. *J Neurol Sci.* 2001;186 (Suppl 1):S37-43. doi: 10.1016/s0022-510x(01)00489-0.
16. Filippi M, Iannucci G, Cercignani M, Assunta Rocca M, Pratesi A, Comi G. A quantitative study of water diffusion in multiple sclerosis lesions and normal-appearing white matter using echo-planar imaging. *Arch Neurol.* 2000;57(7):1017-1021. doi:10.1001/archneur.57.7.1017.
17. Almolla RM, Hassan HA, Raya YM, Hussein RA. Correlation of apparent diffusion coefficient to cognitive impairment in relapsing remittent multiple sclerosis (plaque, peri-plaque and normal appearing white matter). *Egypt J Radiol Nucl Med.* 2016;47:1009-1018. doi: 10.1016/j.ejmm.2016.04.018.
18. Castriota Scanderbeg A, Tomaiuolo F, Sabatini U, Nocentini U, Grasso MG, Caltagirone C. Demyelinating plaques in relapsingremittent and secondary-progressive multiple sclerosis: assessment with diffusion MR imaging. *Am J Neuroradiol.* 2000;21(5):862-868. PMID: 10815661.
19. Mohamed MM, Al-Ani MI, Al Gawwam G, Alrubaye MH, Al-Imam A. Detection of multiple sclerosis lesions in supra- and infra-tentorial anatomical regions by double inversion recovery, flair, and T2 MRI sequences: A comparative study in Iraqi patients. *Al-Rafidain J Med Sci.* 2023;5(Suppl 1):S172-176. doi: 10.54133/ajms.v5i1S.357.
20. Ragheb S, Ekladios M. The value of apparent diffusion coefficient measurement in assessment and follow up of multiple sclerosis patients. *Egypt J Hospital Med.* 2021;82(4):655-662. doi: 10.21608/EJHM.2021.150438.
21. Davoudi Y, Foroughipour M, Torabi R, Layegh P, Matin N, Shoeibi A. Diffusion weighted imaging in acute attacks of multiple sclerosis. *Iran J Radiol.* 2016;13(2):e21740. doi: 10.5812/iranradiol.21740.
22. Terzi M, Atalay K, Incesu L, Diren B, Onar M. Diffusion-weighted magnetic resonance imaging of the brain in multiple sclerosis. *Turk J Neurol.* 2007;13:310-318.
23. Unal S, Peker E, Erdogan S, Erden MI. Is it possible to discriminate active MS lesions with diffusion weighted imaging? *Eurasian J Med.* 2019;51(3):219-223. doi: 10.5152/eurasianjmed.2019.18473.