





Research Article

Recurrence Rate of Pleomorphic Adenoma in Minor Salivary Glands After Surgical Excision: A Retrospective Clinical Study

Ali Hussein Abbas¹ , Yassir Ryadh Al-Khannaq¹ , Auday Mahmood Al-Aneel¹ , Ahmed Fadhel Al-Quisi^{1*} 

¹Department of Oral and Maxillofacial Surgery, College of Dentistry, University of Baghdad, Baghdad, Iraq

Received: 2 December 2023; Revised: 31 December 2023; Accepted: 7 January 2024

Abstract

Background: Pleomorphic adenoma of the minor salivary gland is a rare benign tumor. It commonly occurs in the hard and soft palates. Treatment by surgical excision achieved success in improving the patient's health. **Objective:** To evaluate the recurrence rate after surgical treatment of pleomorphic adenoma in minor salivary glands. **Methods:** This retrospective study included patients who attended the Maxillofacial Surgery Unit in Ghazi Al-Hariri Hospital, Baghdad, from 2019 to 2021, complaining of soft tissue lumps involving the soft and hard palate, buccal mucosa, and upper lip. After the provisional diagnosis of these lesions, a total surgical excision of the tumor with a safe margin of 1 mm was performed, and the biopsy was sent for histopathological examination. A follow-up evaluation was performed for all patients two years after surgery. **Results:** Twenty-three patient data sheets with minor salivary gland pleomorphic adenoma were screened and initially included in this study. Only 12 patients (8 males and 4 females) were eligible, and 11 were excluded. Out of the patients who had total surgical excision, two women experienced tumor recurrence during the follow-up period. One had an ulcerated pleomorphic adenoma in the hard palate, and the other had a pleomorphic adenoma in the soft palate with mucosal tethering. **Conclusions:** Wide surgical excision is a successful treatment to decrease the recurrence rate, especially in cases of ulceration and tethering.

Keywords: Minor salivary gland, Pleomorphic adenoma, Surgical excision, Tumor recurrence.

معدل تكرار الورم الحميد متعدد الأشكال في الغدة اللعابية الصغيرة بعد الاستئصال الجراحي: دراسة سريرية بأثر رجعي

الخلاصة

الخلفية: الورم الحميد متعدد الأشكال للغدة اللعابية الصغيرة هو ورم حميد نادر يحدث عادة في الحنك الصلب والرخو. حقق العلاج عن طريق الاستئصال الجراحي نجاحا في تحسين صحة المريض. **الهدف:** تقييم معدل التكرار بعد العلاج الجراحي للورم الحميد متعدد الأشكال في الغدة اللعابية الصغيرة. **الطريقة:** شملت هذه الدراسة بأثر رجعي المرضى الذين حضروا إلى وحدة جراحة الوجه والفكين في مستشفى غازي الحريري، بغداد من 2019 إلى 2021، ويشكون من كتل الأنسجة الرخوة التي تشمل الحنك الرخو والصلب، والغشاء المخاطي الشدقي، والشفة العليا. بعد التشخيص المؤقت لهذه الآفات، تم إجراء استئصال جراحي كامل للورم بهامش آمن قدره 1 مم، وتم إرسال الخزعة للفحص النسيجي. تم إجراء تقييم متابعة لجميع المرضى بعد عامين من الجراحة. **النتائج:** تم فحص ثلاثة وعشرين سجل بيانات للمرضى المصابين بورم غدي متعدد الأشكال في الغدة اللعابية البسيطة وأدرجت في البداية في هذه الدراسة. كان 12 مريضا فقط (8 ذكور و 4 إناث) مؤهلين وتم استبعاد 11 مريضا. من بين المرضى الذين خضعوا للاستئصال الجراحي الكلي، عانت امرأتان من تكرار الورم خلال فترة المتابعة. كانت أحدهما مصابة بورم غدي متعدد الأشكال منقرح في الحنك الصلب، والأخرى مصابة بورم غدي متعدد الأشكال في الحنك الرخو مع ربط الغشاء المخاطي. **الاستنتاجات:** الاستئصال الجراحي الواسع هو علاج ناجح لتقليل معدل التكرار، خاصة في حالات تقرح الغشاء المخاطي فوق الورم أو تعشق الورم بالأنسجة العميقة.

* **Corresponding author:** Ahmed F. Al-Quisi, Department of Oral and Maxillofacial Surgery, College of Dentistry, University of Baghdad, Baghdad, Iraq; Email: ahmedquisi@gmail.com

Article citation: Abbas AH, Al-Khannaq YR, Al-Aneel AM, Al-Quisi AF. Recurrence Rate of Pleomorphic Adenoma in Minor Salivary Glands After Surgical Excision: A Retrospective Clinical Study. *Al-Rafidain J Med Sci.* 2024;6(1):50-54. doi: <https://doi.org/10.54133/ajms.v6i1.440>

© 2024 The Author(s). Published by Al-Rafidain University College. This is an open access journal issued under the CC BY-NC-SA 4.0 license (<https://creativecommons.org/licenses/by-nc-sa/4.0/>).



INTRODUCTION

Salivary glands are exocrine glands responsible for saliva secretion. Humans have three major salivary glands (parotid, submandibular, and sublingual) [1]. In addition, more than 800 minor salivary glands are distributed everywhere, including the sinonasal cavity and oral cavity, and might involve the pharynx, larynx, trachea, lungs, and middle ear cavity [2]. However, it is mostly presented along the submucosa of the lip, cheek, soft or hard palate, and floor of the mouth [3]. Tumors, benign or malignant, affect the major and minor salivary glands at different rates. Minor salivary gland tumors represent < 25% of intraoral salivary neoplasms [4], with the majority of tumors being malignant [5]. These tumors have explicit characteristics regarding their frequency, distribution, and clinical behavior [6]. Despite the relatively low frequency of occurrence of these lesions, they represent a diverse group of neoplasms with a vast range of histological types and growth modes. They may appear at any age, mostly occurring for benign lesions in the fourth decade of life [7]. Pleomorphic adenoma of the minor salivary gland is mostly present in the hard palate [5]. Benign lesions of minor salivary glands tend to grow slowly, with an average course being 3–6 years, while malignant lesions are rapid-growing, typically less than one year, which is one of the clinical behaviors that allow differentiation between benign and malignant tumors of minor salivary glands [8,9]. The diagnosis of salivary gland neoplasms remains a mystery due to their complex behavior. Their various micromorphological appearances are related to the underlying cellular mechanisms and differentiation into various histopathological subdivisions with interlocking features. Diagnosis is mainly achieved by utilizing fine needle aspiration (FNA) biopsy, computerized tomography (CT), and magnetic resonance imaging that aid in evaluating the structure and staging of tumors [10]. The most frequently observed clinical presentation of benign lesions is a single, smooth surface with a normal overlying mucosa color. The soft tissue lump is asymptomatic and without adherence to either superficial or deep layers [10]. Minor salivary gland tumors have a high recurrence rate (5–30%) when surgical removal is incomplete, with the possibility of malignant transformation of these benign tumors after recurrence. In addition, the histopathological characteristics of the tumor and the initial surgical treatment may influence the tumor's ability to relapse or transform [11]. No previous clinical study in the literature discussed the surgical excision technique used for these benign tumors and its association with the possible recurrence, and only a few case reports dealt with this subject due to the rare occurrence of such tumors. This study evaluates the recurrence rate after surgical excision of the pleomorphic adenoma involving the minor salivary glands with a 1mm safe margin.

METHODS

This retrospective study included patients who attended the Maxillofacial Surgery Unit in Ghazi Al-Hariri Hospital, Baghdad, from 2019 to 2021 with soft tissue swelling that involved the soft and hard palate, buccal mucosa, and upper lip. The initial diagnosis of these lesions was done by CT scan and FNA biopsy, followed by surgical treatment, which was achieved by total surgical excision with a safe margin of 1 mm (incision on the top of the lesion including the overlying mucosa only; 1 mm beyond the mucosal incision, dissection was commenced till the complete exposure of the lesion, then retrieval of the mass). The biopsy was sent for histopathological study to achieve a definitive diagnosis. A follow-up evaluation was done on all patients for two years after surgery. Patients with a history of recurrent pleomorphic adenoma who were treated with other modalities like radiotherapy or with incomplete records regarding the follow-up and the biopsy were excluded from the study. The preoperative assessment data of all patients included an examination of facial symmetry, regional lymph nodes, and TMJ condition. The intraoral examination included examination of the mass site, size, color, consistency, surface texture, tenderness, tethering to the skin or mucosa, and attachment to the underlying structure. Furthermore, patients were informed about the nature of the surgery and the possible complications that may arise, and they signed an informed consent regarding the steps of the treatment and the unrestricted use of patient data for scientific or academic research purposes. All patients operated under general anesthesia for total surgical excision of the tumor with a safe margin of 1mm, as shown in Figure 1. There were no intraoperative or postoperative complications such as bleeding, paresthesia, infection, pain, or edema.

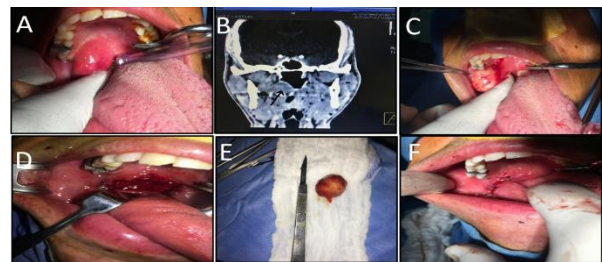


Figure 1: total surgical excision of the pleomorphic adenoma at the junction of hard and soft palate. (A) intraoral clinical examination of the lesion (B) coronal view of the CT scan revealed displaced nasal floor by the tumor mass (C) exposure of the tumor after careful dissection (D) total surgical excision of the lesion with 1 mm safe margin (E) the whole tumor including intact its capsule (F) wound closure.

Data analysis

The collected data was analyzed using the statistical package for social science (SPSS) for Windows software version 26. Chi-square and Fisher exact tests

are utilized for statistical analysis of data. A *p*-value less than 0.05 was considered significant.

RESULTS

Twenty-three patient data sheets that involved pleomorphic adenoma of the minor salivary gland were initially screened for possible inclusion in this study. Only 12 patients (8 males and 4 females) were eligible, and 11 were excluded (6 data sheets had incomplete data, 3 patients were treated with nonsurgical modalities, and 2 patients had recurrent tumors). The remaining twelve patients had lesions affecting different

sites in the oral cavity (7 tumors in the palate, 3 in the buccal mucosa, and 2 in the lip). The size of these tumors ranges from 1 to 3 cm (5 cases size 1-2 cm, 5 cases size 2-3 cm, 2 cases >3cm). Two patients reported recurrence of pleomorphic adenomas during the follow-up period; both were females (aged 31 and 32 years). The first patient presented with an ulcerated pleomorphic adenoma of minor salivary glands of the hard palate, while the other patient presented with a pleomorphic adenoma of the soft palate with mucosal tethering. These two cases were reoperated with a wider surgical excision after the recurrence. The complete, detailed information about the included patients is illustrated in Table 1.

Table 1: Detailed information regarding the variables of the included patients

No.	Sex	Age (year)	Site	Size (cm ²)	Treatment details	Follow-up
1.	Male	35	Soft palate to tonsillar pillar	4	Excision with 1mm safe margin	No recurrence
2.	Male	38	Upper lip	2.5	Excision with 1mm safe margin	No recurrence
3.	Male	28	Hard palate extends to soft palate	3	Excision with 1mm safe margin	No recurrence
4.	Male	40	Upper lip	2.8	Excision with 1mm safe margin	No recurrence
5.	Male	12	Buccal mucosa (cheek)	1.8	Excision with 1mm safe margin	No recurrence
6.	Female	38	Hard Palate	2	Excision with 1mm safe margin (overlying mucosa is ulcerated)	Recurrence after 6 months
7.	Male	32	Buccal mucosa (cheek)	1.9	Excision with 1mm safe margin	No recurrence
8.	Female	31	Soft palate	2.5	Excision with 1mm safe margin (the lesion tethered to the overlying mucosa)	Recurrence after 4 months
9.	Female	35	Buccal mucosa (cheek)	1.5	Excision with 1mm safe margin	No recurrence
10.	Male	36	Soft palate	2	Excision with 1mm safe margin	No recurrence
11.	Male	33	Soft palate	2.1	Excision with 1mm safe margin	No recurrence
12.	Female	32	Soft palate	1.8	Excision with 1mm safe margin	No recurrence

Regarding age and gender, this study showed that pleomorphic adenoma is most prevalent in the fourth decade of life with a male predilection (male to female ratio of 2:1). In addition, this study showed that the soft and hard palate was the most frequent location for this tumor (more than 50% of the cases), followed by the buccal mucosa (25%), and then the upper lip (17%). Furthermore, there were no significant correlations between the recurrence of the tumor and the sex, size or site of these tumors, as shown in Table 2.

Table 2: correlations between study variables and recurrence rate

Variables	Number	Recurrence	<i>p</i> -value
sex	Male	8	0.9*
	Female	4	
Age (year)	< 30	0	1 ^e
	≥ 30	2	
Site of the lesion	palatal	5	0.46*
	others	5	
Size of the lesion	< 2 cm	0	0.51*
	≥ 2 cm	2	

*= Chi square test, ^e= Fissure exact test

DISCUSSION

Pleomorphic adenoma is the most current benign tumor of the salivary gland. Morphologically distinguished by a two-phase paradigm including the epithelial and mesenchymal ingredients. The modulated myoepithelial cells might play an essential role in its histologic distinction by forming an extracellular matrix [12]. Pleomorphic adenoma usually presents clinically as a sluggish-growing, painless lump that might present for several years, according to physical examination, cytology, and histopathology. CT scans and magnetic resonance imaging (MRIs) are helpful techniques to determine the site and size of the neoplasm and its extension to nearby areas, especially bone [13]. Most lip tumors appear intraorally in the mucosa of the lip as solitary lumps or nodules. These tumors enlarge in size with trauma from eating [14]. However, in the current study, some cases present a well-defined nodule in the skin with a small prominence resembling a sebaceous cyst or other benign tumor. This study showed that the most common site of this tumor was the palate, followed by buccal mucosa, and lastly, the upper lip (more than 50%, 25%, and 17%, respectively); these study's results

were close to the results of the recent multicenter study including 1,829 patients with minor salivary gland tumors and reported by Alsanie *et al.* in 2022, which showed that PA most commonly affects the palate (58%), followed by the upper lip (20%), and buccal mucosa 12% [15]. These slight differences might be due to including all benign and malignant tumors of minor salivary glands. In addition, this study showed a male-to-female ratio of 2:1; these results were supported by another study among Jordanian patients [16] and counteracted by another study by Kumaran *et al.* (2019), which showed slight female predilection with a male-to-female ratio of 0.7:0.9, respectively, regarding all salivary gland tumors (major and minor) of benign and malignant histological features [17]. These conflicting results may be due to the limited studies in the literature focusing on pleomorphic adenoma of minor salivary glands. Most of the affected patients (10 patients) in this study were between 31 and 40 years old (5 females and 5 males), and these findings were supported by a study by Gao *et al.* in 2017, which showed that the pleomorphic adenoma of minor salivary glands occurred in the third and fourth decades [18]. The surgical approach for all of these tumors was total surgical excision with a 1mm safe margin, and since these tumors do not invade the periosteum, there was no request to shave the bone. In this study, the recurrence rate after excision of the lesion was low, with only two cases from a total of 12 cases having recurrence; both of these were in females: the first one affecting the minor salivary gland in the hard palate with ulceration of the mucosa, while the second case was in the soft palate and the tumor tethered into the mucosa. A study by Verma *et al.* supports these outcomes due to incomplete excision of the tumor, tearing of the capsule, or tumor effuse during excision that might seed tumor cells into the neighboring tissues, resulting in recurrence, as these tumors often have microscopic pseudopod-like protractions into the adjacent tissues through the capsule [19,20].

Study limitations

Limitations of this study include a small sample size due to the rare occurrence of such tumors in minor salivary glands and a short follow-up period.

Conclusion

A complete surgical excision of a minor salivary gland pleomorphic adenoma with close normal tissues of 1 mm is critical for successful treatment of such tumors with a low recurrence rate following complete excision.

Conflict of interests

No conflict of interests was declared by the authors.

Funding source

The authors did not receive any source of fund.

Data sharing statement

Supplementary data can be shared with the corresponding author upon reasonable request.

REFERENCE

1. Edgar WM, O'Mullane DM, Dawes C, (Eds.), *Saliva and Oral Health*. London: British Dental Association; 2004.
2. Kessler AT, Bhatt AA. Review of the major and minor salivary glands, part 1: anatomy, infectious, and inflammatory processes. *J Clin Imag Sci*. 2018;8(47):1-5. doi: 10.4103/jcis.JCIS_45_18.
3. Ogle OE. Salivary gland diseases. *Dental Clinics*. 2020;64(1):87-104. doi: 10.1016/j.cden.2019.08.007.
4. Wahlberg P, Anderson H, Biörklund A, Möller T, Perfekt R. Carcinoma of the parotid and submandibular glands--a study of survival in 2465 patients. *Oral Oncol*. 2002;38(7):706-713. doi: 10.1016/S1368-8375(02)00007-6.
5. Hyam DM, Veness MJ, Morgan GJ. Minor salivary gland carcinoma involving the oral cavity or oropharynx. *Aust Dent J*. 2004;49(1):16-19. doi: 10.1111/j.1834-7819.2004.tb00044.x.
6. Sarmiento DJ, Morais MD, Costa AD, Silveira ÉJ. Minor intraoral salivary gland tumors: a clinical-pathological study. *Einstein (Sao Paulo)*. 2016;14(4):508-512. doi: 10.1590/S1679-45082016AO3749.
7. Strick MJ, Kelly C, Soames JV, McLean NR. Malignant tumours of the minor salivary glands— A 20-year review. *Br J Plastic Surg*. 2004;57(7):624-631. doi: 10.1016/j.bjps.2004.04.017.
8. Patel CM, Hogarth K, Richards PS. Imaging of salivary glands. *Imaging*. 2013;22(1):20120030. doi: 10.1259/imaging/67453895.
9. SafeAllah MH, Abdulhadi BN, Mahdi AN, Al-Quisi AF. Total superficial parotidectomy: Pros and cons. *KMJ*. 2022;18(2):92-97. doi: 10.36330/kmj.v18i2.10288.
10. Iyer J, Hariharan A, Cao UM, Mai CT, Wang A, Khayambashi P, et al. An overview on the histogenesis and morphogenesis of salivary gland neoplasms and evolving diagnostic approaches. *Cancers*. 2021;13(15):3910. doi: 10.3390/cancers13153910.
11. Rawson K, Kallali B, George A, Nair AK. Minor salivary gland neoplasms of palate: Case series with differential diagnosis and review of literature. *J Indian Acad Oral Med Radiol*. 2017;29(4):321-324. doi: 10.4103/jiaomr.jiaomr_58_17.
12. Nonitha S, Yogesh TL, Nandaprasad S, Maheshwari BU, Mahalakshmi IP, Veerabasavaiah BT. Histomorphological comparison of pleomorphic adenoma in major and minor salivary glands of oral cavity: A comparative study. *J Oral Maxillofac Pathol*. 2019;23(3):356-362. doi: 10.4103/jomfp.JOMFP_91_19.
13. Patigaroo SA, Patigaroo FA, Ashraf J, Mehfooz N, Shakeel M, Khan NA, Kirmani MH. Pleomorphic adenoma of hard palate: an experience. *J Maxillofac Oral Surg*. 2014;13(1):36-41. doi: 10.1007/s12663-012-0448-5.
14. Gelidan AG, Arab K. Rare upper lip pleomorphic adenoma presents as cutaneous skin lesion: Case report. *Int J Surg*

- Case Rep. 2021;85:106142. doi: 10.1016/j.ijscr.2021.106142.
15. Alsanie I, Rajab S, Cottom H, Adegun O, Agarwal R, Jay A, et al. Distribution and frequency of salivary gland tumours: an international multicenter study. *Head Neck Pathol.* 2022;16(4):1043-1054. doi: 10.1007/s12105-022-01459-0.
16. Al-Khtoum N, Qubilat AR, Al-Zaidaneen S, Al Mefleh S, Al-Qudah A. Clinical characteristics of pleomorphic adenoma of salivary glands among Jordanian patients. *J Pak Med Assoc.* 2013;63(3):358–360. PMID: 23914638.
17. Kumaran JV, Daniel MJ, Krishnan M, Selvam S. Salivary gland tumors: An institutional experience. *J Res Dent Sci.* 2019;10(1):12-16. doi: 10.4172/2471-8726.1000150.
18. Gao M, Hao Y, Huang MX, Ma DQ, Chen Y, Luo HY, et al. Salivary gland tumours in a northern Chinese population: a 50-year retrospective study of 7190 cases. *Int J Oral Maxillofac Surg.* 2017;46(3):343-349. doi: 10.1016/j.ijom.2016.09.021.
19. Verma S, Aggarwal S, Garg P, Verma A, Gera M, Yadav SS. Juvenile onset pleomorphic adenoma presenting as giant tumor of parotid gland in a young female. *J Dr NTR Univ Health Sci.* 2021;10(4):286-288. doi: 10.4103/jdrntruhs.jdrntruhs_91_21.
20. Toida M, Shimokawa K, Makita H, Kato K, Kobayashi A, Kusunoki Y, et al. Intraoral minor salivary gland tumors: a clinicopathological study of 82 cases. *Int J Oral Maxillofac Surg.* 2005;34(5):528-532. doi: 10.1016/j.ijom.2004.10.010.